

## Case report

# Adult height following a combined treatment of ketoconazole - cyproterone acetate - leuprolide depot in a boy with atypical McCune-Albright syndrome

Maria Francesca Messina,<sup>1</sup> Tommaso Aversa,<sup>1</sup> Luisa de Sanctis,<sup>2</sup>  
Malgorzata Wasniewska,<sup>1</sup> Mariella Valenzise,<sup>1</sup> Giovanni Battista Pajno,<sup>1</sup>  
Filippo De Luca,<sup>1</sup> Fortunato Lombardo<sup>1</sup>

<sup>1</sup> Department of Pediatrics, University of Messina, Messina; <sup>2</sup> Department of Pediatrics, University of Torino, Torino; Italy

### ABSTRACT

**BACKGROUND:** This study was carried out because of the rarity of peripheral precocious puberty (PPP) in boys with McCune-Albright syndrome (MAS) and the lack of data on adult height of treated MAS males, treatment for this disorder being not as yet standardized. **AIMS:** To report the adult height of a MAS boy with PPP who was treated with ketoconazole – cyproterone acetate – leuprolide depot and to describe some atypical aspects of MAS presentation and course in this boy. **CASE HISTORY:** The case concerns a boy presenting with unilateral macroorchidism, no signs of PPP or initially isolated Sertoli cell activation and MAS mutation that subsequently also activated Leydig cells, thus inducing a change in phenotypic expression. **CONCLUSIONS:** a) In a MAS boy presenting with unilateral macroorchidism and no other signs of PPP, a consecutive involvement of Leydig cells may follow the initially isolated activation of Sertoli cells; b) prolonged treatment with ketoconazole – cyproterone acetate – leuprolide depot may be well tolerated and effective, as demonstrated by the very good adult height outcome recorded in our patient.

**Key words:** Antiandrogens, Final height outcome, GNAS1 gene mutation, Gn-RH analogs, Leydig cells, Sertoli cells, Unilateral macroorchidism

### INTRODUCTION

McCune-Albright syndrome (MAS) is a sporadic and rare disorder which arises from a post-zygotic

gain-of-function mutation at codon 201 of the GNAS1 gene, leading to ligand-independent receptor activation and inappropriate cAMP production.<sup>1,2</sup> It occurs more frequently in girls<sup>3</sup> and is clinically defined by the classic triad of café-au-lait skin lesions, polyostotic fibrous dysplasia and peripheral precocious puberty (PPP). The clinical picture, however, may be very heterogeneous, with 30% of patients showing the classic triad and 70% of them showing only one or two of the cardinal features.<sup>4</sup> In addition to the

#### Address for correspondence:

Prof. Filippo De Luca, M.D., Dipartimento Scienze Pediatriche, Ginecologiche, Microbiologiche e Biomediche, Università di Messina, AOU “G. Martino”, Via Consolare Valeria, 98124 Messina, Italy, Tel.: +39 090 2213157, Fax: +39 090 2212143, e-mail: filippo.deluca@unime.it

Received: 31-03-14, Accepted: 07-07-14

classic triad, a number of other endocrine disorders, including growth hormone and prolactin excess,<sup>5</sup> Cushing's syndrome<sup>6</sup> and hyperthyroidism,<sup>7</sup> have been reported in MAS.

Phenotypic expression of MAS may significantly differ according to gender.<sup>8</sup> In fact, whereas PPP is the most common initial manifestation in girls, it has been reported in only 15% of affected boys.<sup>9</sup> The fact that girls develop PPP more frequently than boys explains why MAS is recognized more frequently and earlier in females.<sup>3,8,9</sup> The vast majority of MAS patients with PPP are female and thus clinical trials on therapeutic management of MAS-related PPP have been focused primarily on girls<sup>10</sup> and the few studies in boys are based on isolated case reports<sup>11-14</sup> or small patient cohorts.<sup>15</sup> Moreover, none of the reported therapeutic trials in boys has followed the treated patients to final height,<sup>11-15</sup> which does not allow the drawing of firm conclusions about the long-term effectiveness of the different regimens.<sup>15</sup>

The aim of the present case report was to describe for the first time the results in terms of adult height of a clinical experience with the therapeutic combination ketoconazole - cyproterone acetate - leuprolide depot, a regimen that had never been tested previously in MAS boys with PPP. Another goal of this report was to describe the very atypical presentation and evolution of MAS in this boy.

## CASE HISTORY

A 4.6-year-old boy with no relevant clinical antecedents, no reliable data about previous growth velocity and no family antecedents of precocious puberty presented to our clinic owing to a painless enlargement of the right testis (10 ml) which had started to swell about 1 year earlier according to the parents' reports. Apart from the monolateral macroorchidism, physical examination revealed neither other abnormalities nor other signs of precocious puberty, such as pubic and/or axillary hair, acne, lowering of the voice pitch and/or typical body odor. Left testis volume was 3 ml and penis size was infantile (4.5 x 1.2 cm). The patient's height was 119.2 cm (+ 2.3 SDS) vs a target height of 181.2 cm (+ 0.8 SDS). Weight and bone age were, respectively, 19.2 kg (+ 0.8 SDS) and 5.5 years. The father's and mother's heights were, respectively, 178.9 and 170.4 cm.

On admission, the endocrinological assessment of both pituitary-gonadal and adrenal function enabled us to exclude both an advanced pubertal activation and the existence of adrenal disorders. By contrast, serum inhibin B was elevated to a pubertal level (153 µg/l, prepubertal reference range 6-72), thus indicating a Sertoli cell activation. Serum β-HCG was undetectable. The coexistence of other endocrine abnormalities, such as hyperthyroidism, hypophosphatemic osteomalacia and pituitary adenomas, was excluded. Although in this case macroorchidism was only monolateral and associated with no other clinical manifestations of MAS and sexual precocity, nevertheless, an atypical and monosymptomatic form of MAS was suspected and this hypothesis was supported by the right testis biopsy results and substantiated by DNA analysis of the samples from right testis biopsy and leukocytes.<sup>16</sup> Both biopsy and DNA analysis were performed some days after the boy's admission.

On the basis of clinical, biochemical and histological data, which were not compatible with an activation of Leydig cells, it was concluded at the time that the activating mutation of the *GNAS1* gene was mainly expressed in Sertoli cells and weakly expressed or absent in Leydig cells.<sup>16</sup> Therefore, no treatment was initially started and the patient was followed over time (Table 1).

During the subsequent 2 years, right testis size and both testosterone and free testosterone serum levels progressively increased (Table 1) and these changes were accompanied by growth velocity and bone maturation acceleration, with a consequent increase of both height SDS and bone age (BA)/chronological age (CA) ratio (Table 1). In light of these changes, when the boy reached the age of 6.6 years we initiated a combined treatment with both ketoconazole (400 mg/daily in 2 divided doses) and cyproterone acetate (50 mg/daily), aiming at both suppressing testicular steroidogenesis<sup>17</sup> and inhibiting the peripheral effects of testosterone and dihydrotestosterone.<sup>18</sup> The initiation of this regimen was followed during the first 12 months by: a) dramatic decrease of right testis size and of both testosterone and free testosterone serum levels (Table 1); b) significant deceleration of growth velocity (Figure 1a); c) arrest of BA/CA ratio increase (Figure 1b). These effects became

**Table 1.** Auxological, clinical, and biochemical data of a boy with McCune-Albright syndrome and precocious puberty treated with ketoconazole, cyproterone acetate and leuprolide depot for many years and monitored up to adult height

|                             |              |       |               |               |                         |                         |                         |                         |                         |       |       |
|-----------------------------|--------------|-------|---------------|---------------|-------------------------|-------------------------|-------------------------|-------------------------|-------------------------|-------|-------|
| CA (yrs)                    | 4.6          | 5.6   | 6.6           | 7.6           | 8.8                     | 10                      | 11                      | 12.6                    | 13                      | 13.6  | 16.6  |
| BA (yrs)                    | 5.6          | 7.6   | 10            | 11.3          | 12.9                    | 12.9                    | /                       | 13.6                    | /                       | 14.6  | 17    |
| BA/CA ratio                 | 1.21         | 1.36  | 1.52          | 1.48          | 1.46                    | 1.29                    | /                       | 1.07                    | /                       | 1.07  | 1.02  |
| Height (cm)                 | 119.2        | 131.1 | 143.3         | 149.9         | 157.2                   | 163.9                   | 167.7                   | 176.5                   | 177.1                   | 180   | 188.5 |
| Height (SDS)                | 2.3          | 3.2   | 4.2           | 4.1           | 4.0                     | 3.8                     | 3.2                     | 2.7                     | 2.3                     | 2.1   | 2.1   |
| Growth velocity (cm/year)   | /            | 11.9  | 12.2          | 6.6           | 7.3                     | 4.2                     | 5                       | 6.8                     | 4.6                     | 4     |       |
| Growth velocity (SDS)       | /            | +6    | +6.2          | +1            | +2.5                    | -1                      | +0.3                    | +2.5                    | -0.5                    | -2    |       |
| Predicted final height (cm) | /            | 187.7 | 191.8         | 193.2         | 187.4                   | 195.4                   | /                       | 195.7                   | /                       | 189.9 |       |
| Right testis (cc)           | 10           | 15    | 18            | 12            | 10                      | 10                      | 12                      | 12-15                   | 12-15                   | 20    | 25    |
| Left testis (cc)            | 3            | 3     | 3             | 3             | 4                       | 3                       | 3                       | 4                       | 4-5                     | 6-8   | 12    |
| Pubic hair stages           | P1           | P2    | P3            | P2            | P2                      | P2                      | P2                      | P2                      | P3                      | P4    | P5    |
| Testosterone (ng/dl)        | 98           | 164   | 191           | 35            | 53                      | 18.6                    | 19.9                    | 55.5                    | 71.8                    | 186.8 | 355   |
| Free-testosterone (pg/ml)   | 1.0          |       | 21.3          | 1.4           | 1.1                     | 0.6                     | 0.8                     | 1.8                     | 2.3                     | 4.8   | 15.2  |
| FSH (mIU/ml)                | <0.1<br>0.4* | <0.1  | 0.3           | 0.8           | 1.2<br>1.8*             | 0.5                     | 0.2                     | 0.2                     | /                       | 0.4   | 2.5   |
| LH (mIU/ml)                 | <0.1<br>0.3* | <0.1  | 0.29          | 0.7           | 1.0<br>11.1*            | <0.1                    | <0.1                    | <0.1                    | /                       | 0.4   | 2     |
| Treatment                   | /            | /     | Keto<br>Cypro | Keto<br>Cypro | Keto<br>Cypro<br>Leupro | Keto<br>Cypro<br>Leupro | Keto<br>Cypro<br>Leupro | Keto<br>Cypro<br>Leupro | Keto<br>Cypro<br>Leupro | /     | /     |

CA = chronological age; BA = bone age; Keto = Ketoconazole (200 mg twice a day), orally; Cypro = Cyproterone acetate (50 mg daily), orally; Leupro = Leuprolide acetate depot (3.75 mg/28 days), intramuscularly

\*peak of FSH and LH after gonadotropin-releasing hormone (GnRH) stimulation test: 100 mcg intravenous

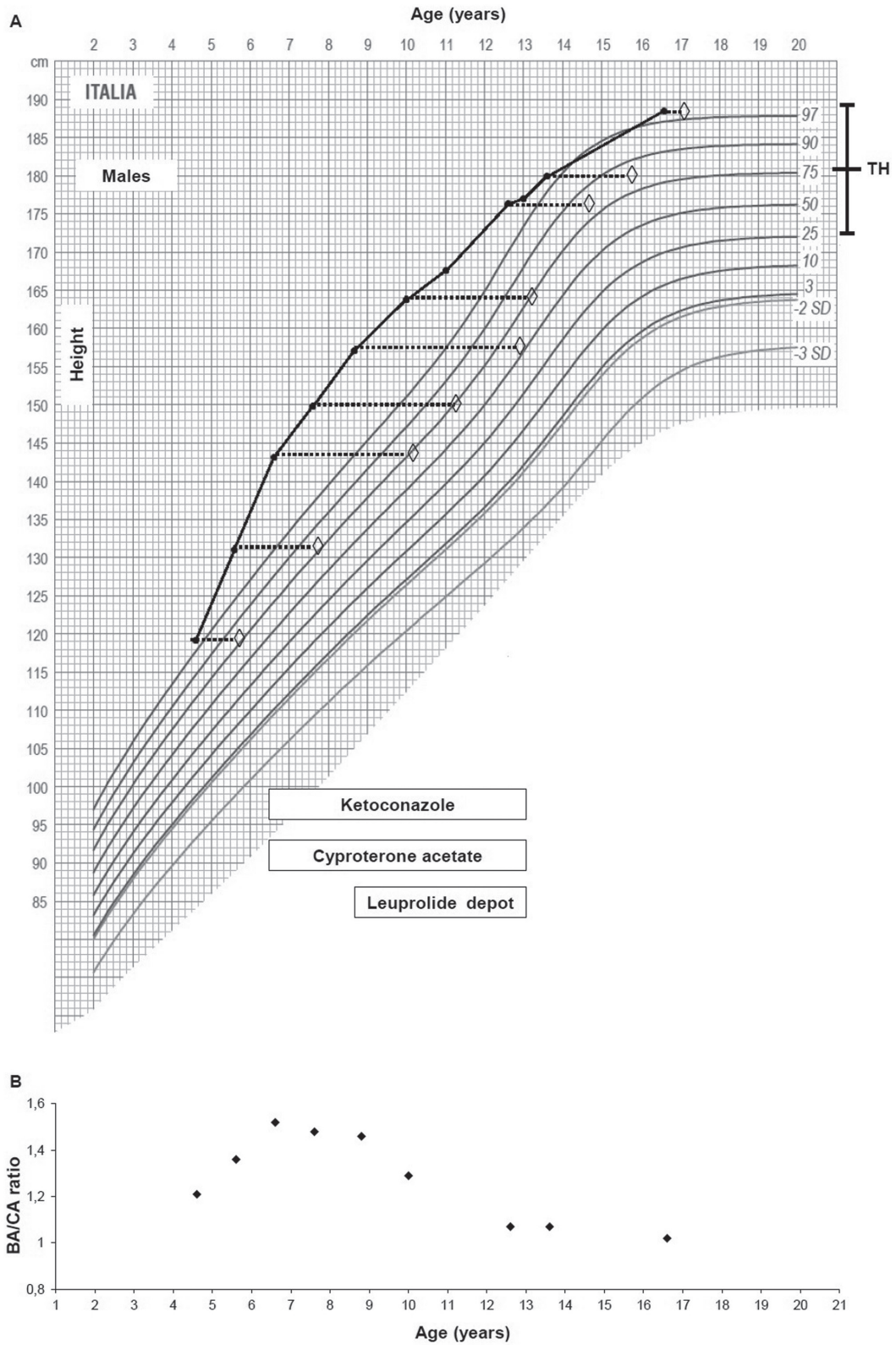
less evident during the 2<sup>nd</sup> year of therapy, probably due to the concomitant onset of central puberty. A spontaneous activation of the pituitary-gonadal axis at the end of the 2<sup>nd</sup> year was, in fact, evidenced by both the enlargement of left testis and the pubertal LH response to GnRH stimulation test (Table 1). On the basis of these findings, when the boy was 8.8 years old (BA 12.9 years), we decided to add a GnRH analogue (leuprolide acetate depot, 3.75 mg/28 days). The inclusion of leuprolide in the therapeutic schedule was followed, during the subsequent 4.2 years, by: a) deceleration of growth and bone maturation velocity; b) reduction of height SDS; c) decrease of BA/CA ratio (Table 1 and Figure 1).

The therapeutic regimen with ketoconazole, cyproterone acetate and leuprolide was definitively stopped at the age of 13 years and its withdrawal was followed by: a) a relevant increase of testosterone, free-testosterone and gonadotropin serum levels; b) significant enlargement of both testes (Table 1). No

side effects and no changes of transaminase serum levels were recorded throughout the overall treatment period (6.4 years).

During follow-up this patient exhibited, at repeated ultrasonographic screening, none of the abnormalities that have frequently been reported in MAS boys,<sup>15,19</sup> neither hypoechoic and hyperechoic lesions nor microlithiasis or focal calcifications. At the age of 16.6 years (BA 17 years), our patient achieved adult height (188.5 cm), which was higher than target height (181.2 cm) and very close to that predicted at the onset of treatment (191.8 cm). At the last examination (16.6 years), our patient exhibited complete pubertal development with adult pubic and axillary hair and penile length, marked testicular asymmetry (Table 1) and no other apparent signs of MAS, neither hypophosphatemic osteomalacia, nor pituitary adenomas, nor hyperthyroidism, nor café-au-lait skin lesions or polyostotic fibrous dysplasia.

Throughout the overall follow-up duration, heights



**Figure 1. a.** Progression over time (12 yrs) of height (●) and bone age (◇) from the first evaluation (4.6 yrs) to the last one (16.6 yrs); horizontal bars indicate the periods of pharmacological treatment; target height (TH) range is also reported. **b.** Progression of bone age (BA)/chronological age (CA) ratio (◇) during the same follow-up period.



and height velocities were measured using Harpenden stadiometers and compared, respectively, with age-matched reference values for boys as classified by Cacciari et al.<sup>20</sup> and Tanner et al.<sup>21</sup> Bone age was assessed according to the method of Greulich and Pyle,<sup>22</sup> whilst predicted height was determined by the Bayley-Pinneau method.<sup>23</sup> Pubic hair stages were estimated according to the standards of Tanner et al.<sup>21</sup>

Serum inhibin B was measured by means of a solid phase sandwich assay, as elsewhere described.<sup>24</sup>

Methods for histological and immunocytochemical examination of testicular tissue have already been described elsewhere,<sup>16</sup> as well as those for molecular analysis of genomic DNA from both leukocytes and a frozen histological section of right testis biopsy.<sup>16</sup>

### ***Longitudinal evaluation data***

All the main auxological, clinical and biochemical data of this boy with MAS during the entire follow-up period (12 years), from the first examination (4.6 years) to the achievement of adult height (16.6 years), are summarized in Table 1. The progression of height and bone age during the same 12-year period is illustrated in Figure 1a, whereas the progression of BA/CA is depicted in Figure 1b.

### ***Right testis biopsy***

As previously reported elsewhere,<sup>16</sup> the histological and immunocytochemical examination of testicular tissue showed an increased diameter of seminiferous tubules. The germinative epithelium was mainly constituted of hyperplastic Sertoli cells, whilst germ cells were variable in number and, for the most part, reduced but focally more numerous, with occasional evidence of incomplete spermatogenesis. In the interstitial tissue, no maturation of fibroblastic cells to Leydig cells was noted, either morphologically or immunocytochemically.<sup>16</sup>

### ***Molecular analysis***

The mutation CGT → TGT at codon 201, resulting in Arg → Cys substitution and classically responsible for MAS, was identified in DNA samples from both leukocytes and right testis biopsy, as elsewhere reported.<sup>16</sup>

## **DISCUSSION**

In this boy, clinical presentation of MAS was

entirely atypical in that none of the typical manifestations of MAS was initially present and the only clinical signs at presentation were macroorchidism and tall stature. Moreover, macroorchidism was only monolateral, as against as that generally reported in MAS boys.

Apart from the present case, in the literature there are only two other MAS boys presenting with unilateral macroorchidism<sup>25,26</sup> and another four who presented with dissociation between testicular enlargement and other pubertal manifestations.<sup>26-29</sup> In two of them, histological examination revealed a picture characterized by Sertoli cell hyperplasia and very few Leydig cells,<sup>28,29</sup> which was very similar to what was found in this case. In fact, in light of the histological findings and the overall presenting picture, we had initially postulated that the activating MAS mutation in our patient was mainly expressed in Sertoli cells and weakly expressed or absent in Leydig cells.<sup>16</sup> Later on we observed in our boy a spontaneous and progressive increase of serum testosterone which was accompanied by growth and bone maturation acceleration. These findings were indicative of a consecutive involvement of Leydig cells, following the initial Sertoli cell activation. On the basis of this longitudinal evolution, we could infer, in agreement with Boyce et al.,<sup>15</sup> that Sertoli cell hyperplasia may initially underlie the originally isolated macroorchidism, whilst Leydig cell activation might develop at a later date.

In this patient, the distinct asymmetry between the two testes persisted from childhood to adulthood, which might suggest that the activating mutation was expressed in only one gonad. The same hypothesis was proposed to explain the persistence of unilateral autonomous ovarian function in an adult woman with MAS.<sup>30</sup> In the latter case however, the mutation was sought in both ovaries but detected only in the affected gonad, whereas in the present case we did not seek the mutation in the left testis. Furthermore, it has to be underlined that similarly in another MAS boy presenting with monolateral macroorchidism, the asymmetry between testes persisted for many years, although the mutation was found in both testes.<sup>25</sup> A further atypical aspect of this case report is the persistent absence of all the MAS manifestations, apart from PPP, until the age of 16.6 years, which confirms

the great phenotypic heterogeneity of this syndrome.

Another aim of this study was to report the results, in terms of adult height outcome, of prolonged treatment with ketoconazole – cyproterone acetate – leuprolide depot. The therapeutic approach that has been most frequently adopted in boys with MAS-related PPP is based on the combination of an antiandrogen to antagonize androgen action at the receptor level, with an aromatase inhibitor in order to block the conversion of androgens to estrogens.<sup>11,12,14,15</sup> Another approach is based on the association of an antiandrogen with the antifungin ketoconazole, a P-450 cytochrome inhibitor which blocks adrenal and testicular androgen biosynthesis.<sup>13</sup> In those cases with secondary pituitary-gonadal axis activation, GnRH agonists should also be employed.<sup>31,32</sup>

The major limitations of all the above therapeutic experiences are the very scanty number of the investigated patients and the short duration of all clinical trials. By contrast, in the present study we followed our patient until the achievement of adult stature, which gave us the opportunity of assessing the long-term effectiveness of the adopted therapeutic regimen. Our own experience showed that the combined treatment with ketoconazole – cyproterone acetate – leuprolide depot was well tolerated and very effective in terms of prolonged normalization of the BA/CA ratio, which enabled our patient to achieve an adult stature even taller than target height.

The combination ketoconazole – cyproterone acetate should probably be applied in preference to the isolated use of either ketoconazole or cyproterone acetate, as suggested by the limited efficacy of both drugs in terms of adult height normalization.<sup>33</sup> However, in a series of five boys with familial male-limited PPP treated only with ketoconazole for a median of 6.2 years, this therapy was able to allow the achievement of an adult height similar to target height.<sup>31</sup>

In the present case we decided to adopt this combined regimen because those based on aromatase inhibitors have no effects on serum testosterone and their efficacy needs to be evaluated indirectly by monitoring growth, bone maturation and pubertal stage evolution.<sup>31</sup>

Finally, thanks to the prolonged follow-up, we have observed in this case another surprising phe-

nomenon, i.e. a significant decrease in right testis size, which followed ketoconazole initiation. This particular finding can probably be explained by the concomitant decrease in testosterone levels. In fact, testosterone alone is known to be able to affect germ cell maturation, irrespectively of FSH activity.<sup>34</sup>

## CONCLUSIONS

a) In a MAS boy presenting with unilateral macrorchidism and no other signs of PPP, a consecutive involvement of Leydig cells may follow the initially isolated activation of Sertoli cells; b) PPP may for a very long time remain the only manifestation of MAS until the age of 16.6 years; c) prolonged treatment with ketoconazole – cyproterone acetate – leuprolide depot may be well tolerated and effective, as demonstrated by the very good adult height outcome recorded in our patient.

## REFERENCES

1. Weinstein LS, Shenker A, Geiman PV, Merino MJ, Friedman E, Spiegel AM, 1991 Activating mutations of the stimulatory G protein in the McCune-Albright syndrome. *N Engl J Med* 325: 1688-1695.
2. Schwindinger WF, Francomano CA, Levine MA, 1992 Identification of a mutation in the gene encoding the alpha subunit of the stimulatory G protein of adenylyl cyclase in McCune-Albright syndrome. *Proc Natl Acad Sci USA* 89: 5152-5156.
3. Lumbroso S, Paris F, Sultan C; European collaborative study, 2004 Activating Gs-alpha mutations: analysis of 113 patients with signs of McCune-Albright syndrome-a European Collaborative Study. *J Clin Endocrinol Metab* 89: 2107-2113.
4. Lumbroso S, Paris F, Sultan C, 2002 McCune-Albright syndrome: molecular genetics. *Pediatr Endocrinol Metab* 15: 875-882.
5. Akintoye SO, Chebli C, Booher S, et al, 2002 Characterization of gsp-mediated growth hormone excess in the context of McCune-Albright syndrome. *J Clin Endocrinol Metab* 87: 5104-5112.
6. Kirk JM, Brain CE, Carson DJ, Hyde JC, Grant DB, 1999 Cushing's syndrome caused by nodular adrenal hyperplasia in children with McCune-Albright syndrome. *J Pediatr* 134: 789-792.
7. Tessaris D, Corrias A, Matarazzo P, et al, 2012 Thyroid abnormalities in children and adolescents with McCune-Albright syndrome. *Horm Res Paediatr* 78: 151-157.
8. Wasniewska M, Matarazzo P, Weber G, et al, 2006 Clinical presentation of McCune-Albright syndrome in

- males. *J Ped Endocrinol Metab* 19: 619-622.
9. Ringel MD, Schwindinger WF, Levine MA, 1996 Clinical implications of genetic defects in G proteins. The molecular basis of McCune-Albright syndrome and Albright hereditary osteodystrophy. *Medicine (Baltimore)* 75: 171-184.
  10. Haddad N, Eugster E, 2007 An update on the treatment of precocious puberty in McCune-Albright syndrome and testotoxicosis. *J Pediatr Endocrinol Metab* 20: 653-661.
  11. Feuillan P, 1994 Albright syndrome. *Curr Ther Endocrinol Metab* 5: 205-209.
  12. Zacharin M, 2005 Paediatric management of endocrine complications in McCune-Albright syndrome. *J Pediatr Endocrinol Metab* 18: 33-41.
  13. Messina MF, Arrigo T, Wasniewska M, et al, 2008 Combined treatment with ketoconazole and cyproterone acetate in a boy with McCune-Albright syndrome and peripheral precocious puberty. *J Endocrinol Invest* 3: 839-840.
  14. Tessaris D, Matarazzo P, Mussa A, et al, 2012 Combined treatment with bicalutamide and anastrozole in a young boy with peripheral precocious puberty due to McCune-Albright Syndrome. *Endocr J* 59: 111-117.
  15. Boyce AM, Chong WH, Shawker TH, et al, 2012 Characterization and management of testicular pathology in McCune-Albright syndrome. *J Clin Endocrinol Metab* 97: 1782-1790.
  16. Arrigo T, Pirazzoli P, De Sanctis L, et al, 2006 McCune-Albright syndrome in a boy may present with a monolateral macroorchidism as an early and isolated clinical manifestation. *Horm Res* 65: 114-119.
  17. Engelhardt D, Weber MM, Miksch T, Abedinpour F, Jaspers C, 1991 The influence of ketoconazole on human adrenal steroidogenesis: incubation studies with tissue slices. *Clin Endocrinol* 35: 163-168.
  18. Laron Z, Kauli R, 2000 Experience with cyproterone acetate in the treatment of precocious puberty. *J Pediatr Endocrinol Metab* 13: 805-810.
  19. Wasniewska M, De Luca F, Bertelloni S, et al, 2004 Testicular microlithiasis: an unreported feature of McCune-Albright syndrome in males. *J Pediatr* 145: 670-672.
  20. Cacciari E, Milani S, Balsamo A, et al, 2006 Italian cross-sectional growth charts for height, weight and BMI (2 to 20 yr). *J Endocrinol Invest* 29: 581-593.
  21. Tanner JM, Whitehouse RH, 1976 Clinical longitudinal standards for height, weight, height velocity, weight velocity, and stages of puberty. *Arch Dis Child* 51: 170-179.
  22. Greulich WW, Pyle SI, 1959 Radiographic atlas of skeletal development of the hand and wrist, (2<sup>nd</sup> edition) Stanford, Stanford University Press.
  23. Bayley N, Pinneau S, 1952 Tables for predicting adult height from skeletal age. *J Pediatr* 14: 432-441.
  24. Lahlou N, Chabbert-Buffet N, Christin-Maitre S, Le Nestour E, Roger M, Bouchard P, 1999 Main inhibitor of follicle stimulating hormone in the luteal-follicular transition: inhibin A, oestradiol, or inhibin B? *Hum Reprod* 14: 1190-1193.
  25. De Luca F, Mitchell V, Wasniewska M, et al, 2008 Regulation of spermatogenesis in McCune-Albright syndrome: lessons from a 15-year follow-up. *Eur J Endocrinol* 158: 921-927.
  26. Khanna G, Kantawala K, Shinawi M, Sarwate S, Dehner LP, 2010 McCune-Albright syndrome presenting with unilateral macroorchidism and bilateral testicular masses. *Pediatr Radiol* 40: Suppl 1: 16-20.
  27. Giovannelli G, Bernasconi S, Banchini G, 1978 McCune-Albright syndrome in a male child: a clinical and endocrinologic enigma. *J Pediatr* 92: 220-226.
  28. Coutant R, Lumbroso S, Rey R, et al, 2001 Macroorchidism due to autonomous hyperfunction of Sertoli cells and G(s)alpha gene mutation: an unusual expression of McCune-Albright syndrome in a prepubertal boy. *J Clin Endocrinol Metab* 86: 1778-1781.
  29. Rey RA, Venara M, Coutant R, et al, 2006 Unexpected mosaicism of R201H-GNAS1 mutant-bearing cells in the testes underlie macro-orchidism without sexual precocity in McCune-Albright syndrome. *Hum Mol Genet* 15: 3538-3543.
  30. Laven JS, Lumbroso S, Sultan C, Fauser BC, 2004 Management of infertility in a patient presenting with ovarian dysfunction and McCune-Albright syndrome. *J Clin Endocrinol Metab* 89: 1076-1078.
  31. Soriano-Guillén L, Lahlou N, Chauvet G, Roger M, Chaussain JL, Carel JC, 2005 Adult height after ketoconazole treatment in patients with familial male-limited precocious puberty. *J Clin Endocrinol Metab* 90: 147-151.
  32. Mieszczyk J, Eugster EA, 2007 Treatment of precocious puberty in McCune-Albright syndrome. *Pediatr Endocrinol Rev* 4: Suppl 4: 419-422.
  33. Almeida MQ, Brito VN, Lins TS, et al, 2008 Long-term treatment of familial male-limited precocious puberty (testotoxicosis) with cyproterone acetate or ketoconazole. *Clin Endocrinol* 69: 93-98.
  34. Spaliviero JA, Jimenez M, Allan CM, Handelsman DJ, 2004 Luteinizing hormone receptor-mediated effects on initiation of spermatogenesis in gonadotropin-deficient (hpg) mice are replicated by testosterone. *Biol Reprod* 70: 32-38.